

# Prevalence and Pathology of Avian Polyomavirus (APV) and Psittacine Beak and Feather Disease Virus (PBFDV) Infections in Taiwan: A Retrospective Study from 2010 to 2014

Duangstuda Thongchan<sup>1</sup> Yen-Li Huang<sup>2</sup> Rupak Khatri-Chhetri<sup>2</sup> Shinn-Shyong Tsai<sup>2</sup> and Hung-Yi Wu<sup>2</sup>

*Received: August, 2015; Accepted: December, 2015*

## Abstract

The objective of the present study was to investigate disease prevalence of Avian polyomavirus (APV) and Psittacine beak and feather disease virus (PBFDV) infection, frequently affecting captive psittacine birds. A total of 163 samples of psittacine birds belonging to 22 genera from a bird farm near by Pingtung, Taiwan was submitted in 2010 and 2014. Each sample was investigated separately using necropsy and histopathological examination by light microscopy. Necropsy examination of APV infected cases revealed were ascities, hydropericardium, splenomegaly, hepatomegaly, suggesting the presence of hemorrhages at subcutaneous tissue, proventriculus, heart and liver. For PBFDV cases, they were characterized by loss of feathers, abnormal feathers shape and overgrowth and irregularity of the surface of the beak. Histopathologic examination of APV case showed characteristic intranuclear inclusion bodies in the liver, kidney, spleen and bone marrow. For PBFDV, a characteristic microscopic finding is the presence of macrophages containing purple intracytoplasmic inclusions in affected esophagus, crop and

<sup>1</sup> Faculty of Agriculture and Technology Rajamangala University of Technology Isan, Surin Campus Thailand

<sup>2</sup> Department of Veterinary Medicine, National Pingtung University of Science and Technology, Taiwan

E - mail : duangstuda59@hotmail.com

feather pulp. The results revealed an APV-positive rate of 16.56% (27/163), a PBFDV-positive rate of 8.59% (14/163) and APV/PBFDV dual infection rate 11.04% (18/163). Overall APV, PBFDV and APV/PBFDV dual infection rate were 36.20% (59/163). In this study the possible outbreak of APV and PBFDV in the future.

**Keywords:** APV; PBFDV; Necropsy; Histopathology; Psittacine Bird

## Introduction

Avian polyomavirus (APV) is included in the genus *Polyomavirus* family *Papovaviridae* among the captive psittacine birds (Lehn, H. and Müller, H., 1986). APV is a non - enveloped, icosahedral double stranded circular DNA virion with a diameter of 45 nm and 4,981 nucleotides in genome length (Dykstra, M.J. and Bozeman, L.H., 1982). Psittacine Beak and Feather Disease Virus (PBFDV) is in the genus *Circovirus* family *Circoviridae*. The virion has a diameter of 14 - 17 nm and a non - enveloped icosahedral with a complete genome size of approximately 2 kb single stranded circular DNA (Bassami, M.R. et al., 2001). PBFDV and APV infection are the most common viral diseases of worldwide psittaciformes (cockatoos, lorikeets and parrots) (Pass, D.A. and Perry, R.A., 1984). At an APV infection, mortality rate reaches up to 100% in fledglings (Krautwald, M.E. et al., 1989). Sometimes APV infection may result in peracute death without clinical signs only. PBFDV causes either a chronic debilitating feather disease in adult birds or a severe, acute disease syndrome in nestling and African Grey parrots (Doneley, R.J.T., 2003; Radial, S.R. and Cross, G.M., 1995). Beak deformities are due to viral infection and replication in the epithelial cell (Pass, D.A. and Perry, R.A., 1984). Survey of PBFDV case have been carried out in both wild and captive psittacine populations and reported virus prevalence rates vary between 10 - 94%, depending on the method of detection. PBFDV causes secondary infections such as bacterial, chlamydial or fungal infections that appear to be the cause of death of most infected birds (Ritchie, B.W. et al., 1989). In Taiwan, a total of 165 psittacine birds belonging to 22 genera were examined between 2002 and 2005. Findings revealed an APV - positive rate of 15.2%, a PBFDV - positive rate of 41.2%, and an APV/PBFDV dual infection rate of 10.3% (Chih, M.H. et al., 2006). APV and PBFDV infection can be diagnosed by the use of histopathology to detect basophilic intranuclear and intracytoplasmic inclusion bodies, but confirmatory diagnosis can be performed by detection of viral DNA (Kulsum, K., 2004). The objective of this study was to present gross, histopathological examination and to investigate prevalence of APV and PBFDV infection in psittacine birds in Taiwan from 2010 to 2014.

## Materials and Methods

Case history: The study population included 163 samples of psittacine birds belonging to 22 genera from a bird farm near by Pingtung city. Samples were submitted in the period of 2010 to 2014 to Department of Veterinary Medicine, National Pingtung University of Science and Technology. Feather and fecal samples were collected from clinically healthy birds exhibiting clinical signs similar to those produced by APV or PBFVDV infection.

### 1. Necropsy

Necropsy observation: Step 1: Obtain the history (age, sex, breed, clinical sign, history of trauma or disease and of any treatment administered). Step 2: Examine the bird externally. Step 3: Open the body. Step 4: Remove the organs and set aside for examination. Step 5: Examine and sample the organs (Corrie, B., 2012).

### 2. Histopathological Examination

Samples of skin, liver, spleen, kidney, lungs, brain and testes or ovary were fixed in a 10% neutral water solution of formalin (Mamom, T. et al., 2010). The tissue samples from 163 birds were sent to histopathology laboratory for slide preparation using conventional method. The formalin fixed samples were processed routinely, embedded in paraffin, and sectioned at 4 microns. The most commonly used stains in histology are hematoxylin and eosin. All slides were examined under light microscope (Axiolab, Zeiss®, Germany) and examined for the presence of any histopathological changes.

### 3. Criteria for Disease Diagnosis

For APV: Gross necropsy finding in deceased chicks often includes pale skeletal musculature and subcutaneous ecchymotic hemorrhages. Results in detection of positive intranuclear inclusion bodies are often seen in the liver, kidneys, spleen, bone marrow, uropygial gland, skin, feather follicles.

For PBFVDV: Include beak abnormalities and is less likely to have severe, classic feather abnormalities seen in cockatoos when the disease was first documented. At necropsy, affected birds often have no gross lesions internally, Results in detection of positive intranuclear or intracytoplasmic inclusions may be seen histologically in the feathers, bursa, thymus, liver, or other organ.

## Results and Discussion

### 1. Necropsy Findings

In the first group, showed high mortality of nestling birds especially breeding flocks (Figure 1). The treated birds showed clinical sign that suggested that they have been infected with APV such as acute death, abdominal distention, and a feather abnormality. Carcass examination also revealed multifocal patchy hemorrhages at subcutaneous tissue (Figure 2). Gross pathology showed ascities, hydropericardium, splenomegaly and hepatomegaly, suggesting the presence of hemorrhages at subcutaneous tissue, proventriculus, heart (Figure 3) and liver (Figure 4). In addition hepatomegaly with multiple white foci. Multifocal ecchymotic hemorrhages were detected at the epicardium of heart, pale liver and bursa of Fabricius. The kidney was pale, associates, changes in the brain and the lung were congested and edematous respectively.

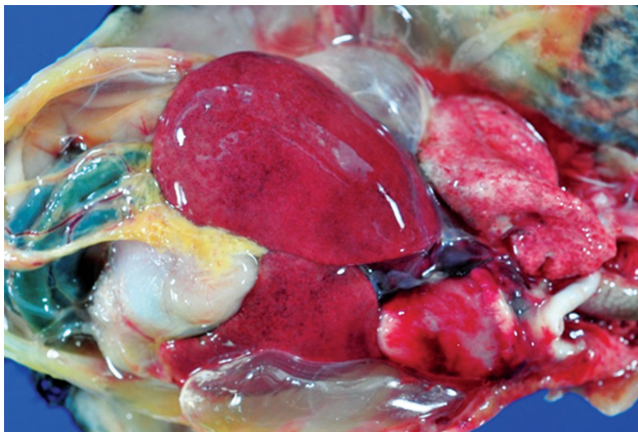


Figure 1 High mortality of nestling cockatiels (*Eclactus roratus*)

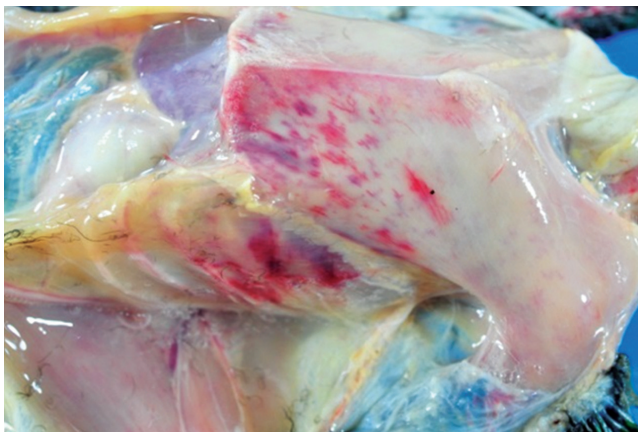


Figure 2 The carcass multifocal patchy hemorrhage at subcutaneous tissue

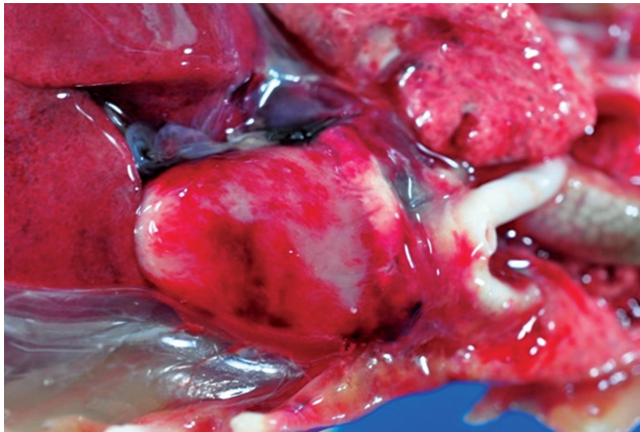


Figure 3 Multifocal ecchymotic hemorrhages were detected at epicardium of heart

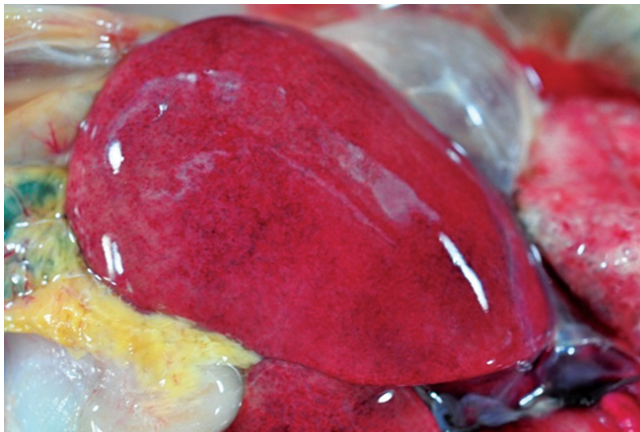


Figure 4 Liver showing hepatomegaly, petechial and ecchymotic hemorrhages

The second group, feathers emerging from the follicle had more hemorrhage, inflammation and necrosis in the region of the cap than normal and it was retained with this sheath. Gross pathology and necropsy showed the characteristic by loss of feathers (Figure 5), abnormally shaped feathers and overgrowth and irregularity of the surface of the beak (Figure 6). In addition, some sample showed bacterial and fungal infections. The results indicate that these birds might be infected with PBFDDV.



Figure 5 The bird loses feathers from head to body



Figure 6 Abnormalities and irregularity of the surface of the beak

APV: The histopathological examination revealed confluent necrosis of the liver and hemorrhages under the epicardium, in the myocardium, and in the kidney interstitium. The most pronouncing microscopic findings were found in the spleen and liver. The liver showed severe congestion with random multifocal hepatic necrosis and hemorrhages. Occasionally, homogeneous pale basophilic intranuclear inclusion body was found in sinusoid - lining cells. Splenic lesion composed of red pulp congestion and severe periarteriolar sheath necrosis indicating splenic necrosis and the presence of lightly basophilic to clear pannuclear inclusion bodies. Karyomegaly, margination of nuclear chromatin and homogeneous pale basophilic intranuclear inclusion body were observed in many splenic periarteriolar sheath cells. In some cases homogeneous pale basophilic intranuclear inclusion bodies were commonly detected in glomerular mesangial cell, epithelium of collecting tubules and papillary ducts of the kidney and mesenchymal cells of lung and heart. These results suggest that the birds might be infected with APV.

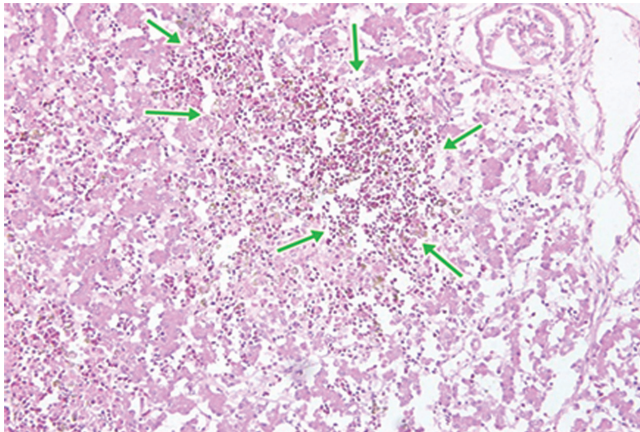


Figure 7 Liver necrosis and signs of acute haemolysis revealed by microscopy

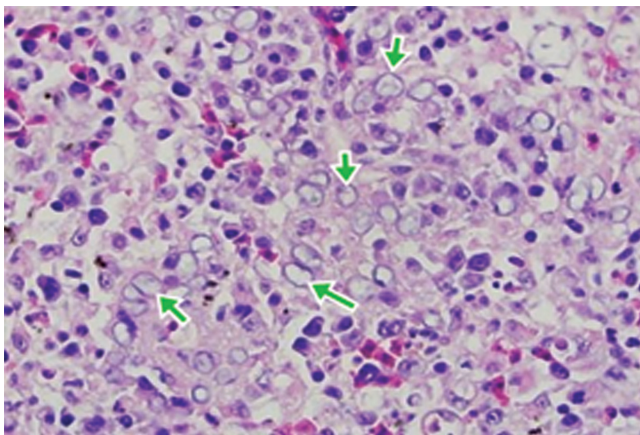


Figure 8 Splenic necrosis and the presence of lightly basophilic to clear pannuclear inclusion

PBFDV: This group showed the dystrophic feather follicles consisting of intercellular attachment of epidermal keratinocytes that had lost their cohesions ends were characterized by marked intracellular edema of the keratinocytes (ballooning degeneration) and necrosis. Large botryoid inclusions were seen in the cytoplasm of macrophages and feather epithelial cells in Feather follicle dermis (Figure 9). Sections of crop and esophagus contained a necrotic pulp with an intense infiltrate of heterophils. Some of these cells contained basophilic nuclear inclusions. Histopathologically, the feather lesions and inclusions were typical of PBFDV. In addition immunosuppression by PBFDV caused a secondary infection that appeared to be the cause of death of most infected birds.

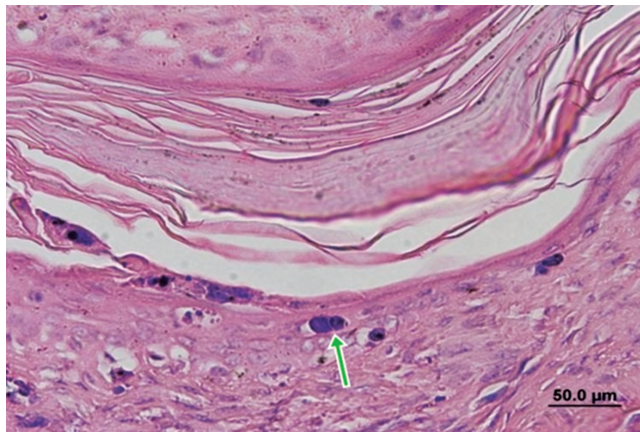


Figure 9 Large botryoid basophilic Inclusions seen in feathe follicles

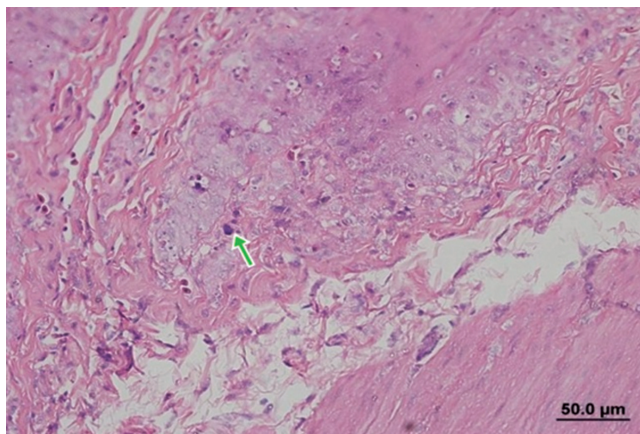


Figure 10 Epithelial cells of crop contained basophilic nuclear inclusions

In the present study, a total of 163 psittacine birds belonging to 22 species were examined between 2010 and 2014 as shown in Table 1. Findings revealed an APV -positive rate of 16.56% (27/163), a PBFDV - positive rate of 8.59% (14/163) and APV/PBFDV dual infection rate of 11.04% (18/163). Total case of APV, PBFDV and APV/PBFDV dual infection rate were 36.20% (59/163).

Table 1 APV and PBFDV necropsy and histopathological findings in healthy and sick psittacine bird

Year	Sample	APV (%)	PBFDV (%)	APV/PBFDV (%)	Total case (%)
2010	45	16 (35.56)	0 (0)	10 (22.22)	26 (57.77)
2011	39	2 (5.13)	3 (7.69)	2 (5.13)	7 (17.94)
2012	28	2 (7.14)	1 (3.57)	1 (3.57)	4 (14.29)
2013	29	6 (20.69)	7 (24.14)	0 (0)	13 (44.83)
2014	22	1 (4.55)	3 (13.64)	5 (22.73)	9 (40.90)
Total	163	27 (16.56)	14 (8.59)	18 (11.04)	59 (36.20)

The prevalence of APV and PBFDV infection in different genera of psittacine birds are provided in Table 2. High test of APV were Lorikeet 11 (6.75%), White - billed caique 8 (4.91%) and Sulpher - crested cockatoo 4 (2.45%). However PBFDV were Conure 6 (3.68%), Lovebird 4 (2.45%) and White - billed caique 2 (1.23%). In addition, APV/PBFDV co - infection were Conure 5 (3.07%), Lorikeet 3 (1.84%) and White - bellied caique 3 (1.84%). In conclusion, the prevalence of co - infection was 36.20% (59/163).

Table 2 Prevalence of APV and PBFDV infection in different genera of psittacine birds

Species	Number of Birds	APV	PBFDV	Co - Infection	Total Case
Macaw	10	-	-	1 (0.61%)	1 (0.61%)
Lorikeet	20	11 (6.75%)	-	3 (1.84%)	14 (8.59%)
Eclectus Parrot	12	1 (0.61%)	1 (0.61%)	2 (1.23%)	4 (2.45%)

Table 2 Prevalence of APV and PBFDV infection in different genera of psittacine birds (Cont.)

Species	Number of Birds	APV	PBFDV	Co - Infection	Total Case
Conure	17	1 (0.61%)	6 (3.68%)	5 (3.07%)	12 (7.36%)
Jardine's Parrot	2	-	-	1 (0.61%)	1 (0.61%)
African grey Parrot	16	-	-	1 (0.61%)	1 (0.61%)
Amazon	2	-	-	-	1 (0.61%)-
Sulphur-Crested Cockatoo	16	4 (2.45%)	-	1 (0.61%)	5 (3.07%)
Cockatiel	9	-	1 (0.61%)	-	1 (0.61%)
White - Bellied Caique	15	8 (4.91%)	2 (1.23%)	3 (1.84%)	13 (7.98%)
Budgerigar	6	-	-	-	-
Lovebird	7	-	4 (2.45%)	1 (0.61%)	5 (3.07%)
Ring - Necked Parakeet	1	1 (0.61%)	-	-	1 (0.61%)
Eastern Rosella	1	1 (0.61%)	-	-	1 (0.61%)
Lineolated Parakeet	1	-	-	-	-
Bourke's Parrot	8	-	-	-	-
Turquoise Parrot	7	-	-	-	-
Scarlet - Chested Parrot	6	-	-	-	-
Senegal Parrot	4	-	-	-	-

Table 2 Prevalence of APV and PBFDV infection in different genera of psittacine birds (Cont.)

Species	Number of Birds	APV	PBFDV	Co - Infection	Total Case
Blue Head Pionus	1	-	-	-	-
Monk parakeet	1	-	-	-	-
Derbyan Parakeet	1	-	-	-	-
Total	163	27 (16.56%)	14 (8.59%)	18 (11.04%)	59 (36.20%)

## Discussion

Avian polyomavirus and Psittacine beak and feather disease are two common viral diseases of psittacine, and prevalent in different species of psittacine birds. In this study, highest prevalence of APV were Lorikeet (6.75%) and Conure (3.68%) for PBFDV. While, Chih, M.H. et al. (Chih, M.H. et al., 2006) reported that the prevalence of APV and PBFDV in African Grey Parrot were 9.3% and 50%, respectively.

In this study for APV infections found were ascities, hydropericardium, splenomegaly, hepatomegaly, suggesting the hemorrhages at subcutaneous tissue, proventriculus, heart and liver. These results related with Özlem, Ö. and Gerry, M. (Özlem, Ö. and Gerry, M., 2003) which described that APV necropsy revealed ascites, hydropericardium, cardiomegaly, splenomegaly, enlargement of the kidney, hepatomegaly and focal hepatic necrosis.

However, infected PBFDV birds in the present study showed the characteristic by loss of feathers, abnormally shaped feathers, overgrowth and irregularity of the surface of the beak. This related to Pass, D.A. and Perry, R.A. (Pass, D.A. and Perry, R.A., 1984), especially progressive degeneration and deformity of the feather and loss as well as beak deformities.

APV infection for present study showed splenic necrosis and the presence of lightly basophilic to clear pannuclear inclusion bodies, karyomegaly, margination of nuclear chromatin and homogeneous pale basophilic intranuclear inclusion body were observed in many splenic periarteriolar sheath cells. The result was consistent with Özlem, Ö. and Gerry, M. (Özlem, Ö. and Gerry, M., 2003) who mentioned that APV most frequently affected the liver and kidney including inclusion bodies which showed on epithelial cells.

However PBFDV showed the characteristic by marked intracellular edema of the keratinocytes (ballooning degeneration) and necrosis. Large botryoid inclusions were detected in the cytoplasm of macrophages and feather epithelial cells in the feather follicle dermis. This was confirmed by Latimer, K.S. et al. (Latimer, K.S. et al., 1991).

## Conclusions

Prevalence and pathology of Avian Polyomavirus (APV) and Psittacine beak and feather disease virus (PBFDV) was studied in order to present gross, histopathological examination and investigate the prevalence of APV and PBFDV infection in psittacine birds in Taiwan during 2010 to 2014. It could be concluded that bordered on APV and PBFDV positive.

## References

- Bassami, M.R., Ypelaar, I., Berryman, D., Wilcox, G.E. and Raidal, S.R. (2001). Genetic Diversity of Beak and Feather Disease Virus Detected in Psittacine Species in Australia. *Virology*. Vol. 279. pp. 392-400
- Chih, M.H., Ching, Y.K. and Hsiang, J.T. (2006). Detection and Sequence Analysis of Avian Polyomavirus and Psittacine Beak and Feather Disease Virus from Psittacine Birds in Taiwan. *Avian Diseases*. Vol. 50. No. 3. pp. 348-353
- Corrie, B. (2012). *How to Necropsy a Bird. A Field Manual for Collection of Specimens to Enhance Diagnosis of Animal Disease*. Department of Veterinary Pathology. University of Georgia, USA 30602-7388
- Doneley, R.J.T. (2003). Acute Beak and Feather Disease in Juvenile African Grey Parrots-an Uncommon Presentation of a Common Disease. *Australian Veterinary Journal*. Vol. 81. Issue 4. pp. 206-207
- Dykstra, M.J. and Bozeman, L.H. (1982). A Light and Microscopy Examination of Budgerian Fledging Disease Virus in Tissue and Cell Culture. *Avian Pathol*. Vol. 11. Issue 1. pp. 11-28
- Krautwald, M.E., Müller, H. and Kaleta, E.F. (1989). Polyomavirus Infection in Budgerigars (Melopsittacus undulatus): Clinical and Etiological Studies. *Zentralbl Veterinarmed B* 36. pp. 459-467
- Kulsum, K. (2004). *Establishment of Serological and Molecular Techniques to Investigate Diversity of Psittacine Beak and Feather Disease Virus in Different Psittacine Birds in South Africa*. Faculty of Natural and Agricultural Sciences. University of the Free State. South Africa
- Latimer, K.S., Rakich, P.M., Steffens, W.L., KircherRitchie, B.W., Niagro, F.D. and Lukert, P.D. (1991). A Navel DNA Virus Associated with Feather Inclusion in Psittacine Beak and Feather Disease. *Veterinary Pathology*. Vol. 28. pp. 300-304

- Lehn, H. and Müller, H. (1986). Cloning and Characterization of Budgerigar Fledgling Disease Virus, an Avian Polyomavirus. *Virology*. Vol. 151. pp. 362-370
- Özlem, Ö. and Gerry, M. (2003). Avian Polyomavirus Infection in Budgerigars (*Melopsittacus Undulatus*) in Turkey. *Turkish Journal of Veterinary and Animal Sciences*. Vol. 28. pp. 409-414
- Mamom, T., Umrongsornthornchai, P. and Trongwongsa, L. (2010). Avian Polyomavirus Infection in Non - Budgerigar Psittacine Birds I Thailand - A Case Report. *The Thai Journal of Veterinary Medicine*. Vol. 40. No. 1. pp. 75-80
- Pass, D.A. and Perry, R.A. (1984). The Pathology of Beak and Feather Disease. *Australian Veterinary Journal*. Vol. 61. No. 3. pp. 69-74
- Radial, S.R. and Cross, G.M. (1995). Acute Necrotizing Hepatitis Caused by Experimental Infection with Psittacine Beak and Feather Disease Virus. *Journal Avian Medicine Surgery*. Vol. 9. pp. 36-40
- Ritchie, B.W., Niagro, F.D., Lukert, P.D., Latimer, K.S., Steffens III, W.L. and Pritchard, N. (1989). A Review of Psittacine Beak and Feather Disease. *Journal of the Association of Avian Veterinarians*. Vol. 3. pp. 143-149